

A Guide to Ultrasound of the Shoulder, Part 1: Coding and Reimbursement

Alan M. Hirahara, MD, FRCS(C), and Alberto J. Panero, DO

Abstract

Ultrasound is an inexpensive, easy, mobile, dynamic study that has many advantages over other imaging modalities. Several studies have shown the need for ultrasound during procedures, with significantly improved outcomes and patient satisfaction. Other studies have also shown that ultrasound has medical and economic advantages over magnetic resonance imaging. With the increased use of ultrasound in the

office, operating room, and during athletic competitions, the need for accurate coding is essential. Reimbursement is viable for both radiologists and non-radiologists. In the coming year, “appropriate use criteria” will be introduced and implemented. Physicians need to be prepared and informed of all the necessary requirements and coming changes regarding the use and billing of ultrasound procedures.

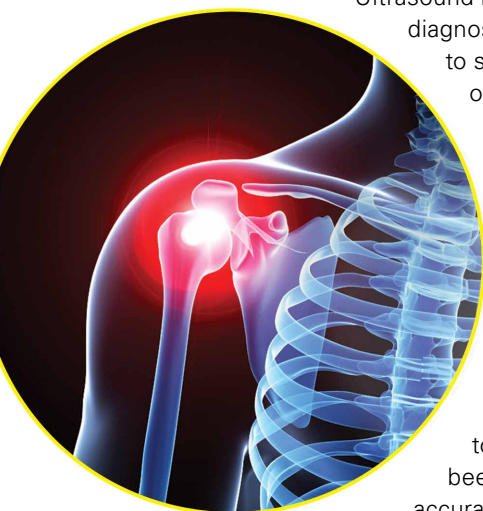Although ultrasound has been around for many years, the technology is underutilized. It has been used primarily by the radiologists and obstetricians-gynecologists. However, orthopedic surgeons and sports medicine doctors are beginning to realize the utility of this imaging modality for their specialties.

Ultrasound has classically been used as a diagnostic tool. This usage is beneficial to sports medicine specialists for on-field coverage at sports competitions to efficiently evaluate injuries without the need for taking the athletes back to the locker room for an x-ray or magnetic resonance imaging (MRI). Ultrasound can quickly assess for damage to soft tissue, joints, and superficial bones. Another of ultrasound’s benefits is its use as an adjunct to treatment. Ultrasound has been shown to vastly increase the accuracy of injections and can be used

in surgery to accurately guide percutaneous techniques or to identify structures that previously required radiation-exposing fluoroscopy or large incisions to find by feel or eye.

Ultrasound is a technician-dependent modality. The surgeon and physician must become facile with the use of the probe and how ultrasound works. The use of the probe is similar to an arthroscope, requiring small movements of the hand to reveal the best imaging of the tissues. Rather than relying on just the patient’s position with an immobile machine, the user must use the probe position and the placement of the patient’s limb or body to optimize the use of ultrasound. Doing so saves time, money, and exposure to dangerous radiation. In a retrospective study of 1012 patients treated over a 10-month period, Sivan and colleagues¹ concluded that the use of clinic-based musculoskeletal (MSK) ultrasound enables a one-stop approach, reduces repeat hospital appointments, and improves quality of care.

With the increased use of ultrasound comes the need to accurately code and bill for the



Authors’ Disclosure Statement: Dr. Hirahara reports that he receives support from Arthrex as consultant fees, royalties, and research support. Dr. Panero reports no actual or potential conflict of interest in relation to this article.

use of ultrasound. According to the College of Radiology, Medicare reimbursements for MSK ultrasound studies has increased by 316% from 2000-2009.² Paradoxically, ultrasound has still been relatively underutilized when compared to the use of MSK MRI.

Diagnostic Ultrasound

Ultrasound is based off sound waves, emitted from a transducer, which are then bounced back off the underlying structures based on the density of that structure. The computer interprets the returning sound waves and produces an image reflecting the quality and strength of those returning waves. When the sound waves are bounced back strongly and quickly, like when hitting bone, we see an image that is intensely white (“hyperechoic”). When the sound waves encounter a substance that transmits those waves easily and do not return, like air or fluid, the image is dark (“hypoechoic”).

Ultrasound’s fundamental advantages start with every patient being able to have an ultrasound: no interference from metal, pacemakers, claustrophobia, or obesity. Contralateral comparisons, sono-palpation at the site of pathology, and real-time dynamic studies allow for a more comprehensive diagnostic evaluation. Doppler capabilities can further expand the usefulness of the evaluation and guide safer interventions. With the advent of high-resolution portable ultrasound machines, these studies can essentially be performed anywhere, and are typically done in a timely and cost-effective manner.

Ultrasound has many diagnostic uses for soft tissue, joint, and bone disorders. For soft tissues, ultrasound can image tears of muscles, tendons, and ligaments; show inflammation like tenosynovitis; demonstrate masses like hematomas, cysts, solid tumors, or calcific tendonitis; display nerve disorders like Morton’s neuroma; or confirm foreign bodies or infections.³⁻⁵ For joint disorders, ultrasound can show erosions on bones, loose bodies, pannus, inflammation, or effusions. For bone disorders, ultrasound can diagnose fractures and, sometimes, even stress fractures. Tomer and colleagues⁶ compared 51 patients with bone contusions and fractures; they determined that ultrasound was most reliable in the diagnosis of long bone diaphyseal fractures. The one disadvantage, especially when compared to MRI, is ultrasound’s inability to fully evaluate intra-articular or deep structures

such as articular cartilage, the glenohumeral labrum, the biceps’ anchor, etc.

Magnetic Resonance Imaging

Ultrasound is similar to MRI as it images tissues and gives us ideas whether that tissue is normal, damaged, or diseased (**Figures 1A, 1B**).

MRI is based on magnetics and large machines that cannot be moved. MRI yields planar images that can only be changed by changing the position of the limb or body in the MRI tube. This can create an issue with obese patients or with postoperative patients who cannot maintain the operated body part in one position for the length of the MRI scan. Ultrasound is better tolerated by patients without the need for claustrophobic large machines (**Table 1**). In 2004, Middleton

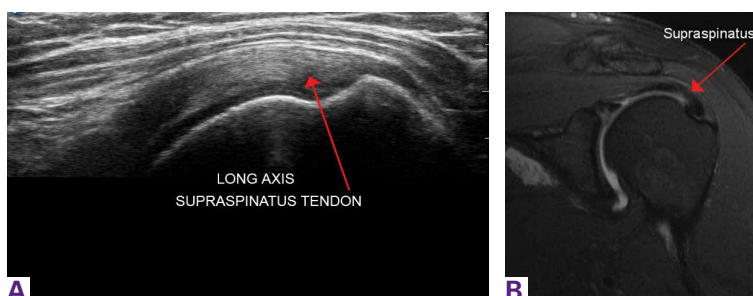


Figure 1. (A) Ultrasound image of left shoulder, long axis view. Normal supraspinatus tendon insertion onto the greater tuberosity. Red arrow indicates tendon. (B) Magnetic resonance imaging of left shoulder, coronal view. Normal supraspinatus tendon insertion onto the greater tuberosity. Red arrow indicates tendon.

Table 1. Ultrasound vs MRI Comparison

Factor	Ultrasound	MRI
Portable examination	Yes	No
Average length of complete examination	10 minutes	45 minutes
Average length of limited examination	2 minutes	-
Resolution	High	High
Extra-articular visualization	Yes	Yes
Intra-articular visualization	Limited	Yes
Dynamic vs static images	Dynamic	Static
Cost	Low	High
Contralateral comparison	Easy	Requires additional study/cost
Pathology marker	Direct sono-palpation	Static external marker
Body habitus limitation	No	Yes

Abbreviation: MRI, magnetic resonance imaging.

and colleagues⁷ surveyed 118 patients who obtained an ultrasound and MRI of the shoulder for suspected rotator cuff pathology; ultrasound had higher satisfaction levels, and 93% of patients preferred ultrasound to MRI.

For rotator cuff tears, ultrasound is also comparable diagnostically with MRI (**Figures 2A, 2B**). In a prospective study of 124 patients, MRI and ultrasound had comparable accuracy for identifying and measuring the size of full-thickness and partial-thickness rotator cuff tears, with arthroscopic findings used as the standard.⁸ A 2015 meta-analysis published in the *British Journal of Sports Medicine* showed that the diagnostic accuracy of ultrasound, MRI, and MR arthrography in the characterization of full thickness rotator cuff tears had >90% sensitivity and specificity. As for partial rotator cuff tears and tendinopathy, overall estimates of specificity were also high (>90%), while sensitivity was as high as 83%. Diagnostic accuracy of ultrasound was similar whether it was performed by a trained radiologist, sonographer, or orthopedist.⁹

Medicare reimbursements for MSK ultrasound studies has increased by 316% in the past decade.² Private practice MSK ultrasound procedures increased from 19,372 in 2000 to 158,351 in 2009.² In 2010, non-radiologists accounted for more ultrasound-guided procedures than radiologists for the first time.¹⁰ MSK ultrasound is still underutilized compared to MRI. This underutilization is also unfortunate economically. The cost of MRIs is significantly higher. According to Parker and colleagues¹⁰, the projected Medicare cost for MSK imaging in 2020 is \$3.6 billion, with MRI accounting for \$2 billion. They also concluded that replacing MSK MRI with MSK ultrasound when clinically

indicated could save over \$6.9 billion between 2006 and 2020.¹¹

Ultrasound-Guided Procedures

MSK ultrasound has gained significant ground on other imaging modalities when it comes to procedures, both in office and in the operating room. The ability to have a small, mobile, inexpensive machine that can be used in real time has dramatically changed how interventions are done. Most imaging modalities used to perform injections or percutaneous surgery use fluoroscopy machines. This exposes the patients to significant radiation, costs significantly more, and usually requires a secondary consultation with radiologists in a different facility. This wastes time and money, and results in potentially unnecessary exposure to radiation.

Accuracy is the most common reason for referral for guided injections. The guidance can help avoid nerves, vessels, and other sensitive tissues. However, accuracy is also important to make sure the injection is placed in the correct location. When injections are placed into a muscle, tendon, or ligament, it causes significant pain; however, injections placed into a bursal space or joint do not cause pain. Numerous studies have shown that even in the hands of experts, “simple” injections can still miss their mark over 30% of the time.¹²⁻¹⁹ Therefore, if a patient experiences pain during a bursal space or joint injection, the injection was not placed properly.

The American Medical Society for Sports Medicine Position Paper on MSK ultrasound is based on a systematic review of the literature, including 124 studies. It states that ultrasound-guided joint injections (USGI) are more accurate and efficacious than landmark guided injections (LMGI), with a strength of recommendation taxonomy (SORT) evidence rating of A and B, respectively.¹⁹ In terms of patient satisfaction, in a randomized controlled trial of 148 patients undergoing knee injections, Sibbitt and colleagues²⁰ showed that USGI had a 48% reduction ($P < .001$) in procedural pain, a 58.5% reduction ($P < .001$) in absolute pain scores at the 2-week outcome mark, and a 75% reduction ($P < .001$) in significant pain and 62% reduction in nonresponder rate.²⁰ From a financial point of view, Sibbitt and colleagues²⁰ also demonstrated a 13% reduction in cost per patient per year, and a 58% reduction in cost per responder per year for a hospital outpatient center ($P < .001$).

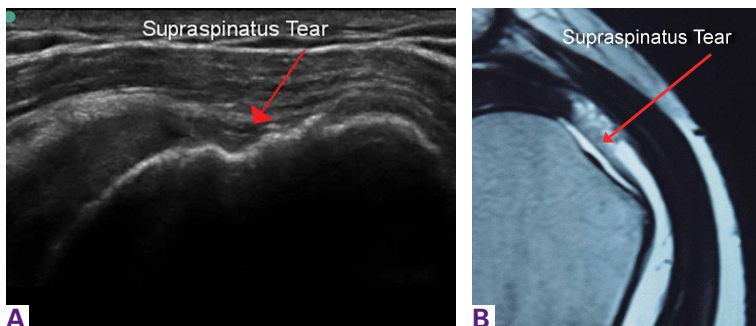


Figure 2. (A) Ultrasound image of left shoulder, long axis view. Torn supraspinatus tendon insertion from the greater tuberosity. Red arrow indicates tear. (B) Magnetic resonance imaging of left shoulder, coronal view. Torn supraspinatus tendon insertion from the greater tuberosity (same patient as in Figure 2A). Red arrow indicates tear.

Coding

Coding for diagnostic MSK ultrasound requires an understanding of a few *current procedural terminology (CPT)* codes (**Table 2**). Ultrasound usage should follow the usual requirements of medical necessity and the *CPT* code selected should be based on the elements of the study performed. A complete examination, described by *CPT* code 76881, includes the examination and documentation of the muscles, tendons, joint, and other soft tissue structures and any identifiable abnormality of the joint being evaluated. If anything less is done, then the *CPT* code 76882 should be used.

New *CPT* codes for joint injections became

effective January 2015 (**Table 3**). The new changes affect only the joint injection series (20600-20610). Previously, injections could be billed with *CPT* code 76942, which was “Ultrasonic guidance for needle placement (eg, biopsy, aspiration, injection, localization device), imaging supervision and interpretation.” This code can still be used, but with only specific injections, when the verbiage “with ultrasound/ image guidance” is not included in the injection *CPT* code descriptor (**Table 4**).

Under the National Correct Coding Initiative (NCCI), which sets Centers for Medicare & Medicaid Services (CMS) payment policy as well as that of many private payers, one unit of

Table 2. Musculoskeletal Ultrasound Codes

<i>CPT</i> Code	Description	Medicare Physician Fee Schedule (National Average)		
		Global Payment	Professional Payment	Technical Payment
76881	Ultrasound, extremity, non-vascular, real time with image documentation; complete	\$116.80	\$32.25	\$84.55
76882	Ultrasound, extremity, non-vascular, real time with image documentation; limited, anatomic specific	\$36.54	\$25.08	\$11.46
76942	Ultrasonic guidance for needle placement (eg, biopsy, aspiration, injection, localization device), imaging supervision and interpretation	\$61.98	\$34.04	\$27.95

Abbreviations: *CPT*, *current procedural terminology*.

Table 3. New Joint Injection Codes (effective January 2015)

<i>CPT</i> Code	Description	Medicare Physician Fee Schedule (National Average)	
		Non-Facility Payment	Facility Payment
20604	Arthrocentesis, aspiration and/or injection, small joint or bursa (eg, fingers, toes); with ultrasound guidance, with permanent recording and reporting	\$73.81	\$47.29
20606	Arthrocentesis, aspiration and/or injection, intermediate joint or bursa (eg, temporomandibular, acromioclavicular, wrist, elbow, or ankle, olecranon bursa); with ultrasound guidance, with permanent recording and reporting	\$81.69	\$54.46
20611	Arthrocentesis, aspiration and/or injection, major joint or bursa (eg, shoulder, hip, knee, subacromial bursa); with ultrasound guidance, with permanent recording and reporting	\$93.51	\$63.42

Abbreviation: *CPT*, *current procedural terminology*.

service is allowed for CPT code 76942 in a single patient encounter regardless of the number of needle placements performed. Per NCCI, "The unit of service for these codes is the patient encounter, not number of lesions, number of aspirations, number of biopsies, number of injections, or number of localizations."

Per the Radiology section of the NCCI, "Ultrasound guidance and diagnostic ultrasound (echography) procedures may be reported separately only if each service is distinct and separate. If a diagnostic ultrasound study identifies a previously unknown abnormality that requires a therapeutic procedure with ultrasound guidance at the same patient encounter, both the diagnostic ultrasound and ultrasound guidance procedure codes may be reported separately. However, a previously unknown abnormality identified during ultrasound guidance for a procedure should not be reported separately as a diagnostic ultrasound procedure."

Under the Medicare program, the *International Classification of Diseases 10th Revision (ICD-10)* code selected should be based on the test results, with 2 exceptions. If the test does not yield a diagnosis or was normal, the physician should use the pre-service signs, symptoms, and conditions that prompted the study. If the

test is a screening examination ordered in the absence of any signs or symptoms of illness or injury, the physician should select "screening" as the primary reason for the service and record the test results, if any, as additional diagnoses.

Modifiers must be used in specific settings. In the office, physicians who own the equipment and perform the service themselves (or the service is performed by an employed or contracted sonographer) may bill the global fee without any modifiers. However, if billing for a procedure on the same day as an office visit, the -25 modifier must be used. This indicates "[a] significant, separately identifiable evaluation and management service." This modifier should not be used routinely. If the service is performed in a hospital, the -26 modifier must be used to indicate that the professional service only was provided when the physician does not own the machine (Tables 2, 3, 4). The payers will not reimburse physicians for the technical component in the hospital setting.

Reimbursement

In general, medical insurance plans will cover ultrasound studies when they are medically indicated. However, we recommend checking with each individual private payer directly, in-

Table 4. Codes Used With CPT Code 76942

CPT Code	Description	Medicare Physician Fee Schedule (National Average)	
		Non-Facility Payment	Facility Payment
20526	Injection, therapeutic (eg, local anesthetic, corticosteroid), carpal tunnel	\$79.18	\$59.47
20527	Injection, enzyme (eg, collagenase) palmar fascial cord (Dupuytren's cord) post enzyme injection	\$86.70	\$69.15
20550	Injection(s) single tendon sheath, or ligament, aponeurosis (eg, plantar "fascia")	\$60.07	\$42.91
20551	Injection(s) single tendon sheath, or ligament, aponeurosis (eg, plantar "fascia") single tendon origin/insertion	\$61.50	\$43.98
20552	Injection(s), single to multiple trigger point(s) 1 or 2 muscle(s)	\$55.78	\$38.62
20553	Injection(s), single to multiple trigger point(s) 3 or more muscle(s)	\$64.72	\$43.98
20612	Aspiration and/or injection of ganglion(s) cyst any location	\$61.86	\$42.91

Abbreviation: CPT, current procedural terminology.

cluding Medicare. Medicare Part B will generally reimburse physicians for medically necessary diagnostic ultrasound services, provided the services are within the scope of the physician's license. Some Medicare contractors require that the physician who performs and/or interprets some types of ultrasound examinations be capable of demonstrating relevant, documented training through recent residency training or post-graduate continuing medical education (CME) and experience. Medicare does not differentiate by medical specialty with respect to billing medically necessary diagnostic ultrasound services, provided the services are within the scope of the physician's license. Some Medicare contractors have coverage policies regarding either the diagnostic study or ultrasound guidance of certain injections, or both.

Payment policies for beneficiaries enrolled in Medicare Part C, known as the Medicare Advantage plans, will reflect those of the private insurance administrator. The Medicare Advantage plan may be either a health maintenance organization (HMO) or a preferred provider organization (PPO). Private insurance payment rules vary by payer and plan with respect to which specialties may perform and receive reimbursement for ultrasound services. Some payers will reimburse providers of any specialty for ultrasound services, while others may restrict imaging procedures to specific specialties or providers possessing specific certifications or accreditations. Some insurers require physicians to submit applications requesting ultrasound be added to their list of services performed in their practice. Physicians should contact private payers before submitting claims to determine their requirements and request that they add ultrasound to the list of services.

When contacting the private payers, ask the following questions:

- What do I need to do to have ultrasound added to my practice's contract or list of services?
- Are there any specific training requirements that I must meet or credentials that I must obtain in order to be privileged to perform ultrasound in my office?
- Do I need to send a letter or can I submit the request verbally?
- Is there an application that must be completed?
- If there is a privileging program, how long will it take after submission of the application before we are accepted?
- What is the fee schedule associated with these codes?
- Are there any bundling edits in place covering any of the services I am considering performing? (Be prepared to provide the codes for any non-ultrasound services you will be performing in conjunction with the ultrasound services.)
- Are there any preauthorization requirements for specific ultrasound studies?

Documentation Requirements

All diagnostic ultrasound examinations, including those when ultrasound is used to guide a procedure, require that permanently recorded images be maintained in the patient record. The images can be kept in the patient record or some other archive—they do not need to be submitted with the claim. Images can be stored as printed images, on a tape or electronic medium. Documentation of the study must be available to the insurer upon request.

A written report of all ultrasound studies should be maintained in the patient's record. In the case of ultrasound guidance, the written report may be filed as a separate item in the patient's record or it may be included within the report of the procedure for which the guidance is utilized.

As examples of our documentation in the office, copies of 3 of our standard forms are available online at www.amjorthopedics.com: "Ultrasound report of the shoulder" (**Appendix 1**), "Procedure note for an ultrasound-guided injection of cortisone" (**Appendix 2**), and "Procedure note for an ultrasound-guided injection of platelet-rich plasma" (**Appendix 3**).

Appropriate Use Criteria (AUC)

The Protecting Access to Medicare Act of 2014 was an effort to help reduce unnecessary imaging services and reduce costs; the Secretary of Health and Human Services was to establish a program to promote the use of "appropriate use criteria" (AUC) for advanced imaging services such as MRI, computed tomography, positron emission tomography, and nuclear cardiology. AUC are criteria that are developed or endorsed by national professional medical specialty societies or other provider-led entities to assist ordering professionals and furnishing professionals in making the most appropriate treatment decision for a specific clinical condition for an

individual. The law also noted that the criteria should be evidence-based, meaning they should have stakeholder consensus, be scientifically valid, and be based on studies that are published and reviewable by stakeholders.

By April 2016, the Secretary will identify and publish the list of qualified clinical decision support mechanisms, which are tools that could be used by ordering professionals to ensure that AUC is met for applicable imaging services. These may include certified health electronic record technology, private sector clinical decision support mechanisms, and others. Actual use of the AUC will begin in January 2017. This legislation applies only to Medicare services, but other payers have cited concerns and may follow in the future.

Conclusion

Ultrasound is being increasingly used in varying specialties, especially orthopedic surgery. It provides a time- and cost-efficient modality with diagnostic power comparable to MRI. Portability and a high safety profile allows for ease of implementation as an in-office or sideline tool. Needle guidance and other intraoperative applications highlight its versatility as an adjunct to orthopedic treatments. This article provides a comprehensive guide to billing and coding for both diagnostic and therapeutic MSK ultrasound of the shoulder. Providers should stay up to date with upcoming appropriate use criteria and adjustments to current billing procedures.

Dr. Hirahara is Orthopedic Surgeon, private practice, Sacramento, California. Dr. Panero is Physical Medicine and Rehabilitation Physician, private practice, Sacramento, California.

Acknowledgement: The authors would like to thank Val Veitengruber, CPC, CPCO, CHCO, CMCS, CMSCS, for her help in preparing this manuscript.

Address correspondence to: Alan M. Hirahara, MD, FRCS(C), 2801 K St., #330, Sacramento, CA 95816 (tel, 916-732-3000; fax, 916-733-8914; email, ahirahara@sacortho.net).

Am J Orthop. 2016;45(3):176-182. Copyright Frontline Medical Communications Inc. 2016. All rights reserved.

References

1. Sivan M, Brown J, Brennan S, Bhakta B. A one-stop approach to the management of soft tissue and degenerative musculoskeletal conditions using clinic-based ultrasonography. *Musculoskeletal Care.* 2011;9(2):63-68.
2. Sharpe R, Nazarian L, Parker L, Rao V, Levin D. Dramatically increased musculoskeletal ultrasound utilization from 2000 to 2009, especially by podiatrists in private offices. Department of Radiology Faculty Papers. Paper 16. <http://jdc.jefferson.edu/radiologyfp/16>. Accessed January 7, 2016.
3. Blankstein A. Ultrasound in the diagnosis of clinical orthopedics: The orthopedic stethoscope. *World J Orthop.* 2011;2(2):13-24.
4. Sinha TP, Bhoi S, Kumar S, et al. Diagnostic accuracy of bedside emergency ultrasound screening for fractures in pediatric trauma patients. *J Emerg Trauma Shock.* 2011;4(4):443-445.
5. Bica D, Armen J, Kulas AS, Young K, Womack Z. Reliability and precision of stress sonography of the ulnar collateral ligament. *J Ultrasound Med.* 2015;34(3):371-376.
6. Tomer K, Kleinbaum Y, Heyman Z, Dudkiewicz I, Blankstein A. Ultrasound diagnosis of fractures in adults. *Akt Traumatol.* 2006;36(4):171-174.
7. Middleton W, Payne WT, Teeffey SA, Hidebolt CF, Rubin DA, Yamaguchi K. Sonography and MRI of the shoulder: comparison of patient satisfaction. *AJR Am J Roentgenol.* 2004;183(5):1449-1452.
8. Teeffey SA, Rubin DA, Middleton WD, Hildebolt CF, Leibold RA, Yamaguchi K. Detection and quantification of rotator cuff tears. Comparison of ultrasonographic, magnetic resonance and arthroscopic finding in seventy-one consecutive cases. *J Bone Joint Surg Am.* 2004;86-A(4):708-716.
9. Roy-JS, Braën C, Leblond J, et al. Diagnostic accuracy of ultrasonography, MRI and MR arthrography in the characterization of rotator cuff disorders: a meta-analysis. *Br J Sports Med.* 2015;49(20):1316-1328.
10. Parker L, Nazarian LN, Carrino JA, et al. Musculoskeletal Imaging: Medicare use, costs, and potential for cost substitution. *J Am Coll Radiol.* 2008;5(3):182-188.
11. Eustace J, Brophy D, Gibney R, Bresnihan B, FitzGerald O. Comparison of the accuracy of steroid placement with clinical outcome in patients with shoulder symptoms. *Ann Rheum Dis.* 1997;56(1):59-63.
12. Partington P, Broome G. Diagnostic injection around the shoulder: Hit and miss? A cadaveric study of injection accuracy. *J Shoulder Elbow Surg.* 1998;7(2):147-150.
13. Rutten M, Maresch B, Jager G, de Waal Malefijt M. Injection of the subacromial-subdeltoid bursa: Blind or ultrasound-guided? *Acta Orthop.* 2007;78(2):254-257.
14. Kang M, Rizio L, Prybicien M, Middlemas D, Blacksin M. The accuracy of subacromial corticosteroid injections: A comparison of multiple methods. *J Shoulder Elbow Surg.* 2008;17(1 Suppl):61S-66S.
15. Yamakado K. The targeting accuracy of subacromial injection to the shoulder: An arthrographic evaluation. *Arthroscopy.* 2002;19(8):887-891.
16. Henkus HE, Cobben M, Coerkamp E, Nelissen R, van Arkel E. The accuracy of subacromial injections: A prospective randomized magnetic resonance imaging study. *Arthroscopy.* 2006;22(3):277-282.
17. Sethi PM, El Attrache N. Accuracy of intra-articular injection of the glenohumeral joint: a cadaveric study. *Orthopedics.* 2006;29(2):149-152.
18. Naredo E, Cabero F, Beneyto P, et al. A randomized comparative study of short term response to blind injection versus sonographic-guided injection of local corticosteroids in patients with painful shoulder. *J Rheumatol.* 2004;31(2):308-314.
19. Finnoff JT, Hall MM, Adams E, et al. American Medical Society for Sports Medicine (AMSSM) position statement: interventional musculoskeletal ultrasound in sports medicine. *Br J Sports Med.* 2015;49(3):145-150.
20. Sibbitt WL Jr, Peisajovich A, Michael AA, et al. Does sonographic needle guidance affect the clinical outcome of intra-articular injections? *J Rheumatol.* 2009;36(9):1892-1902.