



Making the Most of Ultrasound-Guided Regional Anesthesia

THERESA BOWLING, MD

Director of Regional Anesthesia
Integrated Anesthesia Associates
Fairfield Division
Shelton, Conn.

Assistant Professor
Frank H. Netter MD School of Medicine at Quinnipiac University
North Haven, Conn.

WESLEY KNAUFT, MD

Chairman of Anesthesiology
Saint Mary's Hospital
Trinity Health of New England
Waterbury, Conn.

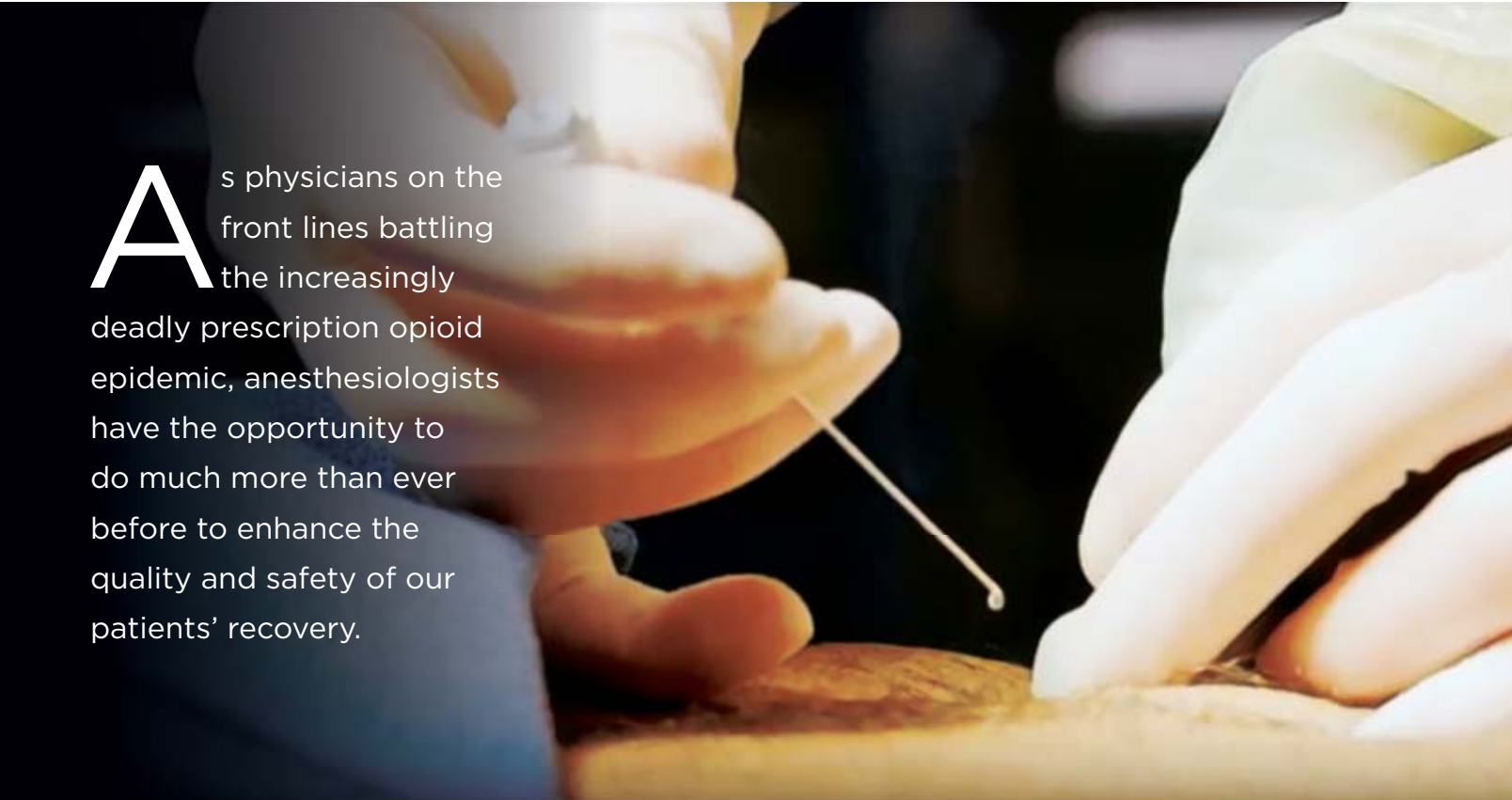
NISHANT SHAH, MD

Partner, Midwest Anesthesia Partners
Medical Director
Illinois Sports Medicine and Orthopedic Surgery Center
Morton Grove, Ill.

SANJAY SINHA, MD

Director, Regional Anesthesia
Director, Regional Anesthesia Acute Pain Fellowship
St. Francis Hospital
Hartford, Conn.

Dr. Bowling reported that she is a consultant to FUJIFILM SonoSite.
The other authors reported no relevant financial disclosures.



As physicians on the front lines battling the increasingly deadly prescription opioid epidemic, anesthesiologists have the opportunity to do much more than ever before to enhance the quality and safety of our patients' recovery.

First described in the 1990s, the use of ultrasound-guided regional anesthesia (UGRA) has dramatically increased in recent years, facilitated by the widespread availability of small portable ultrasound machines with high-resolution imaging. Numerous comparative studies and meta-analyses have demonstrated that UGRA is the most effective technique to achieve the central requirement for safe, successful regional anesthesia blocks—namely, ensuring the optimal distribution of local anesthetic around the target nerves and minimizing the risk for injury to surrounding structures. Compared with other techniques, UGRA also produces longer block durations, faster onset times, improved block success and a reduced need for opioids.

Increasingly, UGRA has been incorporated into enhanced recovery pathways (ERPs) at many centers, including those where the authors of this article practice. ERPs have been shown to substantially reduce costs, complications, length of stay (LOS) and readmissions in nearly all surgical specialties by standardizing the care of the surgical patient with evidence-based best practices. In this review, we present our individual experiences with a variety of common and novel applications of UGRA in a roundtable format. We also discuss the advantages of UGRA, its use in the OR versus a non-OR setting, and strategies to improve the speed, safety and success of ultrasound-guided nerve blocks. Additionally, we provide guidance on selecting an ultrasound system for anesthesiology.

Advantages of Ultrasound Guidance

Dr. Sinha: The ability to visualize the target nerves and surrounding structures with ultrasound has several important benefits, including expanding the array of blocks that anesthesiologists can perform safely, swiftly and successfully. In the past, when we had to rely on surface landmarks, paresthesia, clicks and nerve stimulation as the needle was advanced, certain blocks, such as the supraclavicular brachial plexus nerve block, were only performed by experienced physicians due to the risk for serious complications, such as pneumothorax. By enabling us to image the plexus, rib, pleura and subclavian artery, ultrasound has substantially improved the safety of this block, which is now commonly performed for surgeries of the upper extremities.

Dr. Knauff: Being able to see and avoid dangerous structures around nerves reduces the risk of intravascular injection, and observing the distribution of local anesthetic around the nerve allows us to safely decrease the volume of the injection, lowering the patient's risk for local anesthesia systemic toxicity (Figure 1). Moreover, by making it easier to perform blocks quickly and efficiently, ultrasound guidance improves surgical workflow.

Dr. Bowling: Current guidelines for postoperative pain management strongly recommend the use of multimodal opioid-sparing techniques, including regional anesthesia. Robust evidence—and experience at our center—has demonstrated that the use of UGRA can

dramatically reduce or even eliminate surgical patients' exposure to narcotics during the perioperative and postoperative period. About one in 15 patients develops a dependence on prescription opioids given after surgery, so by using opioid-sparing techniques, such as UGRA, anesthesiologists can play an important role in helping our patients avoid a future of opioid addiction and the devastation it causes for patients and their families.

Advancements in Ultrasound-Guided Peripheral Nerve Blocks

Dr. Shah: Along with improving postoperative pain control—one of the major determinants of LOS—and reducing opioid usage and associated side effects, UGRA techniques also increase patient satisfaction. UGRA expedites functional recovery after a variety of joint procedures, including total knee arthroplasty (TKA), one of the most common elective surgeries in the United States. With minimal use of opioids at our center, our patients are typically able to start ambulating 30 to 60 minutes after TKA and ready for discharge within two hours. One factor that helps our patients get back on their feet quickly is our use of a relatively new peripheral nerve block: the adductor canal block (ACB), performed with precision under ultrasound guidance. In a recent systematic review, ACB was shown to accelerate recovery, while reducing LOS, costs and complications, compared with an older technique, the femoral nerve block, which often causes quadriceps weakness that can lead to postoperative falls.

Dr. Sinha: Controlling posterior knee pain after TKA or cruciate ligament surgeries, such as anterior cruciate ligament repair, is an important component of a comprehensive multimodal strategy for postoperative analgesia. Using ultrasound imaging, our practice developed a new regional block for knee surgery for

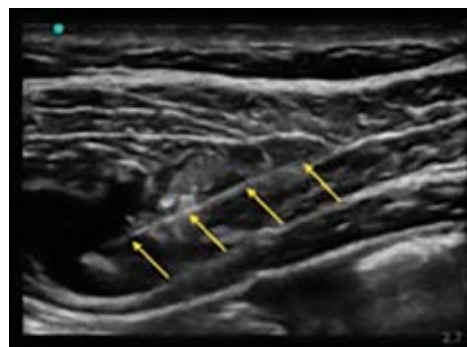

Figure 1.

An ultrasound scan showing the needle tip at the targeted location and the spread of local anesthetic. Image quality is an important factor in avoiding dangerous structures around nerves, reducing the risk of intravascular injection and safely decreasing injection volume.

controlling posterior knee pain—infiltration between the popliteal artery and capsule of the posterior knee (iPACK)—that can only be performed under ultrasound guidance. Now used around the world, iPACK selectively blocks the innervation of the posterior knee joint while sparing the main trunks of the tibial and common peroneal nerves, thereby preserving sensorimotor function of the leg and foot. Usually combined with ACB or the femoral nerve block, iPACK may offer advantages over a sciatic nerve block, a technique that can cause foot drop and delayed diagnosis and treatment of surgically induced injury to the common peroneal nerve. In our practice, iPACK has also replaced selective tibial nerve block, which provides pain control without foot drop, but has the drawbacks of reducing sensation in the sole of the foot and weakening plantar flexion.

Improved Outcomes for Breast, Abdominal And Hip Surgeries With UGRA

Dr. Bowling: After the introduction of UGRA to our practice, we felt comfortable trying new blocks that we would not previously have considered without ultrasound guidance (Figure 2). For example, after we started using UGRA, we introduced a hip fracture protocol that included using a fascia iliaca compartment block preoperatively to reduce or eliminate the need for opioids in our elderly patients, which, in turn, has helped decrease the incidence of perioperative delirium. For our patients undergoing breast surgery, thoracic paravertebral catheters placed under ultrasound guidance have become the standard of care and foundation for the Narcotic-Sparing Breast Surgery Program we instituted for patients undergoing mastectomy, with or without immediate reconstruction. This program has markedly improved the quality of recovery after major breast surgery and provided patients with the option of same-day discharge.

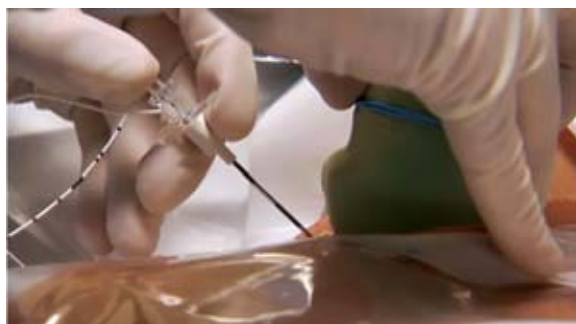

Figure 2.

An external perspective of an ultrasound transducer helping guide a needle during the administration of regional anesthesia. As anesthesiologists gain more experience with ultrasound-guided regional anesthesia, procedures will continue to evolve with the development of new nerve blocks, including those for the chest and abdominal wall, hip and more.

Dr. Knauff: Our hospital has seen significant improvements in clinical and economic outcomes after implementing an ERP for colorectal surgery that included ultrasound-guided transversus abdominis plane blocks. Opioid usage dropped by 60%, and many patients were able to forgo these highly addictive drugs entirely. In addition, the average LOS for colorectal patients decreased from 6.3 to 4.3 days, resulting in increased revenues of \$750,000 over a three-year period (nearly \$5,000 in additional revenue per patient). As part of the Connecticut Surgical Quality Collaborative, all 28 of Connecticut's acute care hospitals are currently working to establish opioid-sparing ERPs.

Administering UGRA in the OR Versus Preoperatively

Dr. Shah: It is best to perform upper and lower extremity blocks in the preoperative setting, before surgery, as this allows the patient to provide tangible information that can help with performing the block. Moreover, a block done in the pre-op bay allows for preemptive analgesia, which can decrease the need for narcotics and anesthesia both intraoperatively and postoperatively (Figure 3). Some publications also suggest that the performance of blocks, even with ultrasound guidance, is safer when the patient is awake and can provide feedback about the block's effects. All of these factors allow for a better episode of care for the patient. For blocks without a motor component, such as certain truncal and abdominal blocks, anesthesiologists may want to perform these blocks in the OR. Since the patient is asleep and not cognizant of discomfort, the block can be performed more quickly and without the need for topical local anesthetic. It is also easier to position the patient and improve ergonomics for optimal block performance.

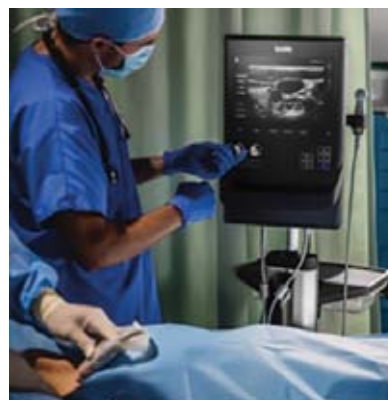

Figure 3.

Point-of-care ultrasound systems enable teams to administer regional nerve blocks, wherever the patient is, efficiently and accurately in a variety of settings, both perioperatively and postoperatively.

Dr. Bowling: Because of the increased efficiency of performing nerve blocks under direct ultrasound visualization, we are able to place all of our blocks in the pre-op area without causing any delays in on-time starts for surgical cases. By standardizing protocols for nerve blocks, including type and volume of local anesthetic and the use of adjuncts, we have streamlined the process, reducing variability in outcomes. We are also able to track nerve block success by provider, thereby creating the opportunity for quality improvement, which is an important component of ERPs.

Dr. Knauff: Our hospital has a dedicated block room staffed with block nurses and equipped with ultrasound machines and all the medications needed to perform UGRA, and treat any complications that may arise. After administering the block, the patient is transferred to the OR for the procedure. However, certain blocks, such as those of the fascial plane, are administered after induction of anesthesia because that is much more comfortable for the patient. For these cases, we have block carts and ultrasound machines that are wheeled into the OR.

Nerve Block Success Strategies

Dr. Sinha: Since the ultimate goal is to put the needle tip right next to the target and inject the local anesthetic

to surround the nerve, it is essential to always be aware of where the needle tip is and avoid dangerous structures. Since this can sometimes be challenging, if there is any uncertainty about where the needle tip is, instead of proceeding blindly—which can be dangerous—either realign the transducer relative to the needle or inject a small amount of saline and visualize the bolus of fluid to help locate the needle tip.

Dr. Bowling: Certain probe maneuvers apply to all nerve blocks. To optimize the ultrasound image, the mnemonic PART (pressure, alignment, rotation, tilt) is useful. Pressure compresses underlying subcutaneous adipose tissues, thus shortening the distance to the target. It can also be used to compress a vein or push an anatomic structure out of the path of the needle pass. Alignment (“sliding”) is used to locate the structure of interest and position it optimally on the screen for needle advancement. Tilt (“rocking” of the probe) facilitates bringing the face of the transducer perpendicular to the underlying target to maximize the number of returning echoes and achieve the best image quality.

Dr. Shah: There are many subtleties to performing nerve blocks, including understanding how to use a 2D ultrasound image to guide needle maneuvers safely and successfully in a 3D patient. It is useful for novices to take a training course, watch videos and practice on

What to Look for in an Ultrasound System for Anesthesiology

Point-of-care ultrasound machines have become increasingly sophisticated. As anesthesiologists who use ultrasound-guided regional anesthesia as the standard of care in our practices, we have the following joint recommendations for users who are considering purchasing an ultrasound system. Look for these elements:

- **Excellent image quality.** Being able to visualize nerves and surrounding structures clearly is the most important feature that an ultrasound system must have to optimize your chances of placing regional anesthesiology blocks successfully.
- **A variety of transducers.** Variety allows anesthesiologists to select the best transducer for each type of block based on depth of target and type of tissue (nerve, artery, bone, fascia or muscle). Along with an assortment of high-frequency linear probes for superficial blocks and curvilinear probes for deeper blocks, consider getting phased-array probes for point-of-care applications, such as the focused assessment with sonography for trauma (FAST) exam to assess hypotensive patients for signs of surgical bleeding; gastric ultrasound to assess risk for aspiration of vomitus by evaluating how full the patient’s stomach is; and for guiding vascular access. Anesthesiologists who work in the cardiac OR will also want a transesophageal echocardiography probe to optimize intraoperative care for the patients undergoing all open heart and thoracic aortic procedures and noncardiac procedures for patients with known or suspected cardiovascular pathology, as recommended in recent guidelines from the Society of Cardiovascular Anesthesiologists.²
- **Needle visualization.** A number of ultrasound platforms include software to enhance visualization of the needle as it advances toward the target, making it easier to keep the tip in clear view.
- **Portability.** When placing a large number of nerve blocks, easily portable equipment is important, especially for anesthesiologists working in small pre-op bays.
- **Durability.** The system must be sturdy because machines frequently get banged into walls, and transducers may be dropped as they are wheeled in and out of the OR or pre-op bay.
- **Recording capability.** The system should be able to document the performance of the blocks through still-image captures or loops for insurance company billing purposes.
- **Ease of use.** The easier the machine is to use, the less time it will take practitioners to understand its functions. More bells and whistles do not make a better machine.
- **Responsive customer service that is available 24/7.** Essential if the practitioner has trouble with a machine because immediate expert help is available from the manufacturer at any hour of the day or night, including weekends.

a mannequin or phantom, all of which will help them develop the necessary hand-eye coordination. It is also important to use small, subtle hand movements and to recognize that the needle is easiest to visualize when it is running parallel to the probe footprint. Needle insertion points can have a significant effect on needle visualization, and can determine the clarity with which one can visualize the needle during the procedure. Also, one needs to be cognizant of the common mistake of moving the needle and probe at the same time during angle adjustments.

The Value of Incorporating UGRA in ERPs

Dr. Knauff: One of the core elements of ERPs is to promote analgesia without opioids. A large body of evidence has demonstrated that UGRA is an ideal technique to achieve this goal, while also significantly improving the safety and quality of surgical care. While ERPs are sometimes misunderstood to be “fast-track surgery,” the true objective is to enhance “every” aspect of the patient’s surgical experience. By using opioid-sparing techniques like UGRA, anesthesiologists add value to surgical care by making the patient’s recovery as safe, successful and pain-free as possible.

Dr. Shah: Although ERPs are relatively new for joint surgeries, a rapidly growing body of evidence—including the first cohort review of the safety benefits of ERPs for outpatient hip and knee replacement, published in 2018 by our group —has revealed that this approach has many advantages.¹ Compared with traditional care, ERPs substantially reduce LOS and hospital costs. They also expedite recovery after total joint arthroplasty with no significant differences in complications or readmissions. Moreover, ERPs have been shown to be superior

to traditional treatment for the management of the various afflictions of the postoperative period, including pain control. Along with these impressive and economic benefits, ERPs that include UGRA also increase patient satisfaction from a pain and mobility standpoint: Many of our patients refer friends and relatives to our center for surgical care, or return themselves to have their other knee replaced or undergo other joint procedures as needed.

Dr. Bowling: The guiding principle of medicine is, “First, do no harm.” By leveraging the latest evidence and most advanced opioid-sparing techniques, including the growing array of novel applications of UGRA that may offer advantages over older techniques, ERPs serve that core principle. As physicians on the front lines battling the increasingly deadly prescription opioid epidemic—which each year claims more American lives than car accidents—anesthesiologists have the opportunity to do much more than ever before to enhance the quality and safety of our patients’ recovery. Along with helping them heal faster with less pain after invasive procedures, we also have the right tools and techniques to help our patients achieve a safer, healthier future over the long term by sparing them exposure to narcotic drugs, thereby protecting our patients from one of the most dangerous harms of surgery.

Dr. Bowling developed and led the Regional Anesthesia Program at the Stamford Hospital, in Connecticut, and in 2012 founded the Stamford School of Regional Anesthesia. Dr. Knauff is also affiliated with Woodland Anesthesiology Associates, PC. Dr. Sinha is also the lead anesthesiologist and board member of the Connecticut Joint Replacement Institute in Hartford and is affiliated with Woodland Anesthesiology Associates, PC. Dr. Shah also serves as the head of the outpatient total joint replacement program at Illinois Sports Medicine and Orthopedic Surgery Center.

References

1. Shah RR, Cipparrone MA, Gordon AC, et al. Is it safe? Outpatient total joint arthroplasty with discharge to home at a freestanding ambulatory surgical center. *Arthroplasty Today*. 2018;4(4):484-487.
2. Thys DM, Brooker RF, Cahalan MK, et al. Practice guidelines for perioperative transesophageal echocardiography. An updated report by the American Society of Anesthesiologists and the Society of Cardiovascular Anesthesiologists Task Force on Transesophageal Echocardiography. *Anesthesiology*. 2010;112(5):1084-1096.